

# A Modular Surface Gliding Implant (CapFlex-PIP) for Proximal Interphalangeal Joint Osteoarthritis: A Prospective Case Series

Stephan F. Schindele, MD, Stefanie Hensler, MSc, Laurent Audigé, DVM, PhD, Miriam Marks, PhD, Daniel B. Herren, MD, MHA

**Purpose** To evaluate the one-year postoperative clinical and patient-rated outcomes in patients receiving proximal interphalangeal (PIP) joint arthroplasty with a modular surface gliding implant, CapFlex-PIP.

**Methods** 10 patients each with primary osteoarthritis of a single PIP joint were assessed preoperatively (baseline), at 6 weeks, and 3, 6, and 12 months after CapFlex-PIP arthroplasty for lateral stability and range of motion of the affected digit. In addition, patients rated their pain using a numeric rating scale and function and overall assessment of their treatment and condition using the quick Disabilities of the Arm, Shoulder and Hand (*QuickDASH*) and Patient Evaluation Measure (PEM) questionnaires, respectively.

**Results** The mean baseline active mobility of the affected PIP joint increased from 42° to 51° by one year, although this change was not significant. Patients reported reduced pain at one year, which was statistically significant. There was also a significant improvement between baseline and one-year *QuickDASH* (43 points vs 15 points, respectively) and PEM scores (51 vs 25 points, respectively). Absent or low lateral instability was observed in 9 joints at follow-up. All implants remained intact over the one-year postoperative period and there was no migration, osteolysis, or implant fracture. After study completion, 2 patients underwent tenolysis.

**Conclusions** Patients experienced a significant reduction in pain and a trend towards increased mobility. All implants showed complete osteointegration without evidence of radiological migration. Lateral stability improved. (*J Hand Surg Am. 2015;40(2):334–340. Copyright © 2015 by the American Society for Surgery of the Hand. All rights reserved.*)

**Type of study/level of evidence** Therapeutic IV.

**Key words** Arthroplasty, case-series, proximal interphalangeal joint, surface replacement.

**I**N CONTRAST TO OSTEOARTHRITIS of the distal interphalangeal joints, where arthrodesis is the treatment of choice for most patients, most surgeons prefer to preserve motion of the proximal

interphalangeal (PIP) joints.<sup>1–3</sup> Lateral stability of the PIP joint is an important aspect for preserving function, especially of the index and middle fingers, which, together with the thumb, are responsible for

*From the Department of Upper Extremities and Hand Surgery and the Department of Research and Development, Schulthess Clinic, Zurich, Switzerland.*

Received for publication April 24, 2014; accepted in revised form October 23, 2014.

The authors thank Prof. Dr. Maja Bürgi and her team from the School of Engineering, Zurich University of Applied Sciences Winterthur, for their support in the development and manufacturing of the prosthesis and Dr. Melissa Wilhelmi for the copyediting of this manuscript.

The two senior authors (S.F.S. and D.B.H.) received royalties from the KLS Martin Group, Tuttlingen, Germany. These authors and their families did not receive any

further financial payments or benefits from any other commercial entity related to the subject of this article. The implants used in this study were funded by the KLS Martin Group.

**Corresponding author:** Stephan F. Schindele, MD, Schulthess Clinic, Department of Upper Extremities and Hand Surgery, Lengghalde 2, 8008 Zurich, Switzerland; e-mail: [Stephan.Schindele@kws.ch](mailto:Stephan.Schindele@kws.ch).

0363-5023/15/4002-0022\$36.00/0  
<http://dx.doi.org/10.1016/j.jhssa.2014.10.047>


grasping and pinching. Joint stability is influenced by several factors including the integrity of the joint surface, the flexor and extensor tendons, capsular and ligamentous structures, and the intraarticular versus external pressure difference.<sup>4</sup> The requirements for replacement of a well-functioning joint are defined by these factors and must be taken into consideration when designing an implant.

Silicone implants have been most widely used for PIP joint arthroplasty and act as a spacer to prevent bony contact or impingement.<sup>5</sup> Alternately, several anatomically designed metal,<sup>6,7</sup> pyrocarbon,<sup>8</sup> and ceramic<sup>9</sup> implants are total joint arthroplasties directed at restoring joint function. None of these implants, however, fulfill all the requirements for adequate PIP joint replacement. Silicone implants may break or dislocate and, especially on the radial rays, cannot restore sufficient lateral stability to achieve a powerful pinch.<sup>10,11</sup> Ceramic and pyrocarbon implants fail to show osteointegration with possible secondary migration.<sup>12–14</sup> In addition, implant revision remains challenging because most implants require generous bone resection including partial or full release of the collateral ligaments.<sup>15,16</sup>

In order to address these limitations, a modular prosthesis for PIP joint arthroplasty (CapFlex-PIP; KLS Martin Group, Tuttlingen, Germany) was developed to offer primary solid bone anchorage with limited bone resection and improved lateral joint stability as a result of the implant's anatomical congruent joint surfaces and because collateral ligaments are preserved during implantation. This pilot investigation aimed at evaluating the clinical and patient-rated outcomes with this new surface gliding implant one year after surgery. Our hypothesis was that stable osseous integration of the implant would be apparent without radiological signs of loosening, migration, or osteolysis in the first 12 months.

## METHODS

Between September 2010 and November 2011, we selected 10 patients with primary osteoarthritis of a single PIP joint for surgical implantation with the CapFlex-PIP prosthesis. Based on the lack of clinical experience with this new implant, the exclusion criteria were radiographically fixed deviation of the longitudinal axis in the frontal plane of more than 20° and lateral instability to the ulnar or radial side of more than 15°; range of motion (ROM) of less than 20°; extensor or flexor tendon dysfunction; severe cyst formation; and severe bony defect of the affected joint. The study was approved by the local ethics



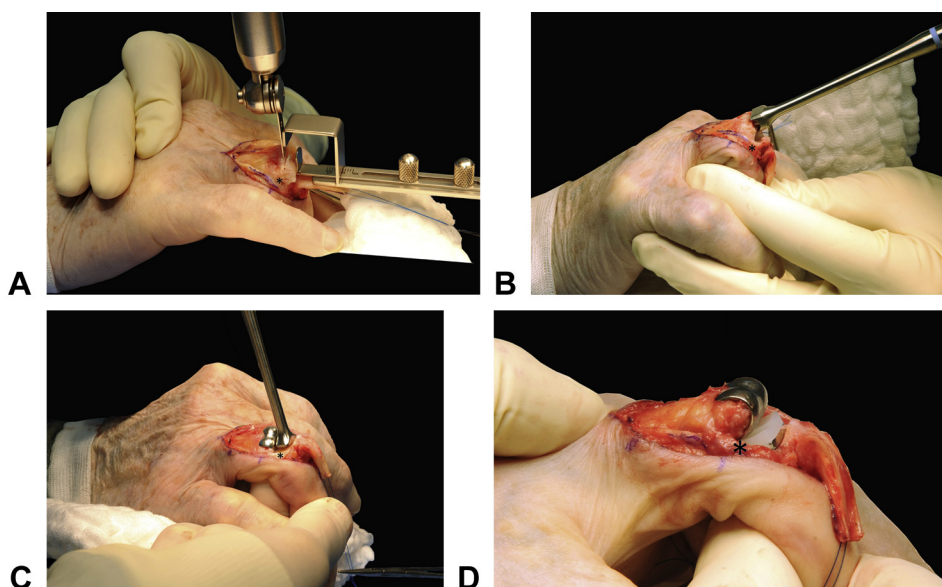
**FIGURE 1:** CapFlex-PIP implant. The proximal and distal cobalt-chrome alloy components (distal 2 out of 3 sizes) with pure titanium coating on backside and inserted polyethylene components.

committee and all included patients gave their written informed consent.

## The modular implant, CapFlex-PIP

The CapFlex-PIP implant (Fig. 1) is a modular gliding surface PIP joint prosthesis consisting of 2 components. The proximal component is a bicondylar cap of cobalt-chrome alloy, and the distal component has an articular surface of ultra-high-molecular-weight polyethylene. Both components have a titanium pore base for cement-free osteointegration. This design provides a classic polyethylene-metal gliding surface known from other implant arthroplasties, although the CapFlex-PIP components have only short pins for endomedullary fixation. The design of CapFlex-PIP corresponds to the anatomical shape of a PIP joint with relatively high contact constraint. The varying height of the polyethylene articular surfaces (ie, 2.1 mm, 3.0 mm, and 4.4 mm) allows for modular adaption of joint stability based on the intraoperative findings to provide ideal collateral ligament tension. In addition, the polyethylene inlay can be changed in cases of revision without removal of the entire distal component.

Before its first clinical use, the CapFlex-PIP implant was tested at the Zurich University of Applied Sciences (ZHAW) (Winterthur, Switzerland) laboratory. Biomechanical analysis and primary press fit experiments with a custom simulator were performed and compared with another approved implant. The CapFlex-PIP implant showed a two-times higher pullout force than the other implant. Furthermore, the abrasion behavior and wear of the sliding alloy metal-polyethylene pair surfaces were checked by simulator testing with one million cycles in liquid medium.



**FIGURE 2:** Implantation of the CapFlex-PIP prosthesis. **A** Initial minimal distal cut at the head with primary resection guide under protection of the collateral ligaments. **B** Shaping for the inner contour with a hollow compactor after performing all resection cuts. **C** Trial proximal component and sizer for determining the correct size of the distal component. **D** Original implanted components. \* = collateral ligament.

Finite-element and risk analyses were also successfully conducted. Together with the risk analysis conducted by ZHAW and the KLS Martin Group, European Conformity certification for the European market was obtained.

### Surgical technique

All surgeries were performed by the 2 senior authors (SFS and DBH) using the dorsal approach described by Chamay.<sup>17</sup> Figure 2 depicts the steps. Using special resection devices, 3 small cuts are performed at the head of the proximal phalanx to shape the bone. A hollow compactor is also used to obtain the most optimal shape of the implant's inner contour. The correct implant size is chosen with special emphasis on avoiding capsule and extensor tendon irritation.

The base of the middle phalanx is prepared to a right-angled surface. A sizer is used to find the correct size of the distal component, and a spacer is used to check the tension required for the correct height of the polyethylene element. The size of the distal component is chosen as large as possible in order to provide maximal bone support. Under fluoroscopy, the correct seating, stability, bony impingement and angulation of the components are then checked with the trial implant. The definitive prosthesis is then inserted using standard techniques for cement-free implants. Finally, the extensor apparatus is securely sutured.

All patients followed a standard rehabilitation protocol involving 3 weeks of postoperative orthosis followed by active mobilization therapy.

### Clinical and patient-rated assessments

The patients were assessed preoperatively, after 6 weeks, and 3, 6, and 12 months following surgery. Lateral stability was judged by the treating surgeon using the valgus-varus method; 3 categories including no, low, and high radial or ulnar instability described the degree of instability, which was compared to the contralateral side. Radial instability indicates that the radial collateral ligament is insufficient and the PIP joint deviates in an ulnar direction. In addition, the active flexion-extension mobility of the PIP joint was measured using a goniometer. Grip strength was recorded with a standard dynamometer. Patient-reported subjective outcome assessment of pain, function, and overall assessment of the treatment and condition was completed using a numeric rating scale (0 indicating no pain and 10 indicating maximum pain), the quick Disability of the Arm, Shoulder and Hand (*QuickDASH*) questionnaire (0 points means no disability and 100 points means complete disability),<sup>18–20</sup> and the Patient Evaluation Measure (PEM), part 2 questionnaire,<sup>21</sup> respectively. The PEM part 2 survey consists of 10 questions. Each question is answered on a 7-point Likert scale. By coding the responses from 0 to 6, the final PEM score

was calculated by summing the values of each item in part 2 and expressing it as a percentage of a maximum possible score lying between 0 and 100 points. A lower PEM score indicates better function.<sup>22</sup> Standard radiographs were used to determine implant breakage, radiolucent lines, implant migration, stress fracture, cyst formation, and longitudinal axis deviation in the frontal plane, the latter of which was divided in minimal, moderate, and large categories: a longitudinal axis deviation between 0° to 5°, between 6° and 15°, and more than 15°, respectively. Intra- and postoperative complications were also documented.

### Statistical analysis

Study parameters were described by standard descriptive statistics including means and standard deviations (SDs) for continuous variables and absolute and relative frequencies for categorical variables. The Wilcoxon signed-rank test was used to assess differences in the subjective and objective clinical parameters between baseline and one-year after surgery. Mean outcome changes with 95% confidence intervals (CIs) are presented. The level of significance was set at  $P \leq .05$ .

### RESULTS

Ten patients (7 men and 3 women), with a mean age of 68 years (SD, 7 y) received a CapFlex-PIP implant: 5 in the index, 2 in the middle, 2 in the ring, and 1 in the small finger. Four patients had previous surgery on their affected hand excluding the PIP joint treated in this study. The mean duration of surgery was 68 minutes (SD, 5 min).

At follow-up, 9 joints had no or low lateral instability, and one showed high radial instability. Mean active flexion-extension mobility increased 9° by final follow-up, a statistically insignificant difference (Table 1). Two digits increased to 85°; although 2 joints showed decreases of 5° to 10°, and 1 joint became entirely stiff. There was a significant decrease in the baseline mean numeric rating scale score for pain. There were also significant decreases in the QuickDASH and PEM scores (Table 1). The patient with high radial instability showed poor functional outcome based on the QuickDASH (57 points) and PEM scores (82 points), although this was associated with a reduction in pain from 8 to 4 after 12 months. All implants remained in place without migration, osteolysis, cyst formation, or fractures (Fig. 3). Deviation in the frontal plane showed an improvement in 5 digits from moderate to minimal and in 1 digit from large to moderate. One digit changed from

TABLE 1. Clinical and Patient-Rated Outcomes

	Baseline		Postoperative Follow-Up				Change Between Baseline and 12-Month Postoperative Follow-Up		P*
	N	Mean (SD)	3 Months		6 Months		12 Months		
			N	Mean (SD)	N	Mean (SD)	N	Mean (SD)	
Range of motion (°)	10	42 (16)	9	53 (17)	10	57 (22)	9	51 (28)	.312
Extension lag (°)	10	18 (8)	9	13 (9)	10	10 (10)	9	9 (9)	.011
Grip strength (kg)	7	22 (6)	9	22 (7)	10	28 (9)	9	27 (8)	.108
Pain relief (NRS)	8	7.9 (0.4)	9	1.7 (1.1)	10	0.7 (1.3)	9	1.1 (1.5)	.018
QuickDASH (0–100)	10	43 (12)	9	17 (8)	9	12 (7)	10	15 (17)	.007
PEM part 2 (0–100)	9	51 (15)	9	19 (13)	9	12 (10)	9	25 (27)	.038

NRS, numeric rating scale.

\*Wilcoxon signed-rank test P value.



minimal to large, and 2 digits (with moderate deviation) remained unchanged one year after surgery.

The adverse events were one case of ossification that developed on the dorsal rim of the proximal phalanx and one case of PIP joint stiffness. Both patients were successfully treated with a secondary tenolysis.

## DISCUSSION

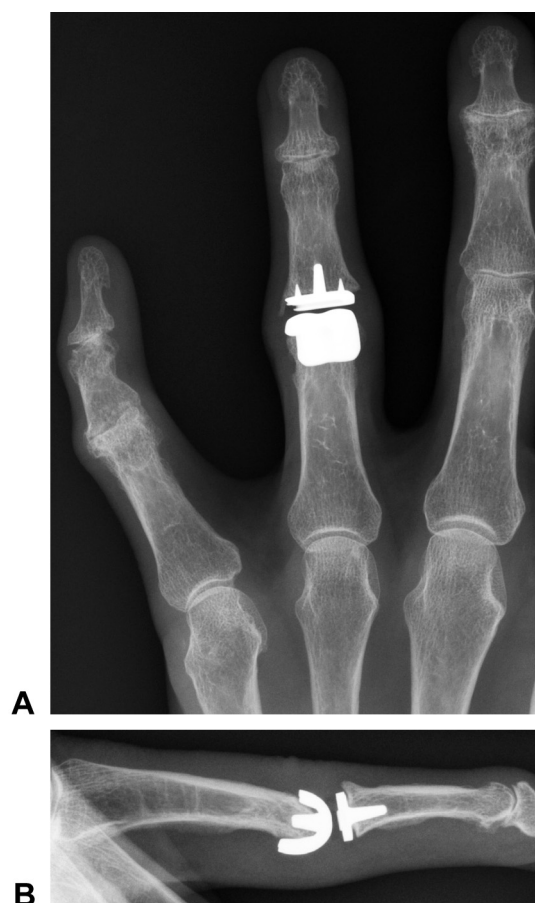
Patients reported significant pain relief and a trend towards improved hand function one year after surgery. No major adverse events, particularly implant migration, were observed, even though the intra- and extramedullary bone fixation of both implant components was minimal. The 2 secondary surgeries were not directly related to the implant, but resulted from the chosen surgical approach.

At follow-up, no or low lateral instability was observed in 9 of the 10 joints. The single patient with marked lateral instability of the PIP joint had an incompetent radial collateral ligament that the implant could not overcome and that became apparent with use of the finger after surgery.

Lateral stability of the PIP joint is an important prerequisite for joint function, especially in the radial rays. Radial stability guarantees sufficient functional pinch grip with the thumb. Some surgeons therefore prefer, especially for the index finger, PIP joint arthrodesis. Silicone implants, with their flexible material properties, can present disadvantages in achieving the required stability.<sup>23,24</sup> Longitudinal axis deviation in the frontal plane and joint instability are therefore difficult to correct with silicone spacers and, at least in theory, surface replacement implants might offer more advantages by providing greater intrinsic stability.<sup>6,7,25,26</sup>

In our patient series, the mean ROM was 51° after one year, which is within the functional ROM of 36° to 86° for the PIP joint.<sup>27</sup> Nevertheless, this outcome is not superior to that of other implants, including silicone spacers. Branam et al<sup>28</sup> compared silicone arthroplasties with resurfacing implants. The mean ROM for the silicone and pyrolytic carbon groups achieved after an average postoperative follow-up period of 45 months was 49° and 53°, respectively.<sup>28</sup>

We opted to use a dorsal approach, which is considered easier to perform and offers, in most cases, a better view of the joint. The disadvantage of this approach, which requires dividing the extensor tendon, is the greater potential of postoperative adhesion and calcification. Pritsch and Rizzo<sup>15</sup> reported necessary revisions in 51 of 76 fingers as a



**FIGURE 3:** Radiograph showing a well-fitted implant without signs of loosening and migration 12 months after surgery. **A** Anteroposterior images. **B** Lateral images.

result of adverse events directly involving the extensor tendons. The surgical approaches, which require dividing the extensor tendon, were associated with more extensor tendon problems. Conversely, the volar approach allows for faster and less restricted rehabilitation, which could have the potential to enhance the ROM. Moreover, the volar approach maintains the integrity of the extensor mechanism and contributes to enhanced pain relief.<sup>29</sup> We have routinely used the volar approach for other PIP joint arthroplasties over the last 20 years.<sup>30–32</sup> As a result of the promising outcome of this preliminary study and further application of CapFlex-PIP, we now use also the volar approach with this implant.

The CapFlex-PIP implant provided pain reduction in our patients, which is comparable with 2 studies that focused on silicone and/or pyrocarbon implants.<sup>26,33</sup> Daecke et al<sup>33</sup> reported a significant reduction in pain during exercise for patients with either silicone or pyrolytic implants. The mean preoperative visual analog scale score of 8.1 for both groups decreased to 0.7 and 2.7 respectively, by the

35-month postoperative follow-up. Bravo et al<sup>26</sup> also reported improvements in pain experienced by 35 patients who underwent pyrolytic carbon arthroplasties. The preoperative visual analog scale score of 6 decreased to 1 after 37 months of follow-up.

The *QuickDASH* and PEM scores of our patients significantly improved from the preoperative ratings. Daecke et al<sup>33</sup> found similar outcomes with patients who underwent arthroplasty with one of 3 different PIP joint implants: silicone spacers, pyrocarbon implants, and titanium-polyethylene implants. The subjective functionality measured with the original DASH questionnaire improved from 57 to 19 points for silicone spacers, 68 to 48 points for pyrocarbon implants, and 65 to 42 points for titanium-polyethylene implants 3 years after surgery.

One of the main concerns associated with a new surface arthroplasty is the primary and secondary stability of the components. The CapFlex-PIP relies on press fit fixation, which is used for modern knee arthroplasties. Due to precontouring of the proximal component with a special modulator, only short pins need to be inserted into the medullary canal. This offers an easier surgical technique compared with that required for other PIP joint surface implants. These short pins secure the rotational stability and the backside of the implant ensures maximal surface for osteointegration with the titanium coating. All of our implants remained in the inserted position and showed complete osteointegration. In particular, implant osteointegration was directly observed in 2 joints that required tenolysis. No migration occurred with any of the implants throughout the entire follow-up period and there were also no signs of loosening or radiolucent lines. With press fit fixation, important bone stock can be preserved and offers an advantage if revision surgery, such as conversion to a silicone spacer or joint arthrodesis, may be necessary.

Two patients needed secondary tenolysis greater than a year after arthroplasty. One patient had extensive dorsal ossification and stiffness. Such ossifications are known from other implant arthroplasties of the hip or elbow<sup>34,35</sup> and represent soft tissue calcifications mainly around tendons. We assume that the extensive tendon exposure and preparation associated with the dorsal surgical approach provoked the calcification process. The second adverse event involved axis deviation with insufficiency of the radial collateral ligament. The reason for this deviation could be a combination of a secondary lesion of the collateral ligament together with minor malpositioning of the proximal component in

the frontal plane. Several studies each reported a high incidence of deviation associated with surface replacement arthroplasties. Chung et al<sup>36</sup> had 3 cases of joint dislocation out of 21 inserted pyrocarbon joints 12 months after surgery. Of 31 pyrolytic implant arthroplasties, 15 cases of implant loosening and 5 dislocations were observed after a mean follow-up of 55 months.<sup>37</sup> In a 10-year follow-up study of 12 patients with 15 pyrocarbon PIP joint implants, Reissner et al<sup>38</sup> recorded 8 implant migrations within the first 2 years. These adverse events remained stable within the 10-year follow-up period and only one additional implant migration was seen between 3 and 10 years post-surgery. Moreover, the revision incidence seems higher for surface gliding implants compared to silicone arthroplasty.<sup>15,32,39</sup> Daecke et al<sup>33</sup> reported a revision incidence of 11% for silicone spacers, 27% for titanium devices, and 39% for pyrocarbon prostheses after a mean follow-up of 35 months. Pritsch and Rizzo<sup>15</sup> confirmed this observation and found that the number of reoperations per finger for pyrocarbon prostheses and metal-plastic surface replacement was 1.5 and 1.8 respectively, although the majority of secondary surgeries were done for soft tissue complications.

This study has some limitations. Firstly, the indication for this new prosthesis was restricted to patients with almost ideal joint conditions. Little deviation of the joint axis, minimal lateral instability, sufficient ROM, intact extensor and flexor tendons, no cyst formation, and no protrusion of the affected joint were the prerequisites for implantation. Our results need to be confirmed in a larger study including less strict indication criteria. Secondly, the surgeries were performed by 2 experienced surgeons who were involved in the implant's design. Nevertheless, all study evaluations were carried out by independent observers. Lastly, the small patient series limits the statistical power of this study.

Based on our early results, we continue to use the CapFlex-PIP implant and have widened the indications for its use. Initial trials with the volar approach show interesting results and we hope that with meticulous soft tissue handling, the results can be improved. Nonetheless, this implant still requires careful systematic evaluation over years. A special online registry has been created to monitor these patients on a regular basis.

## REFERENCES

1. Olivier L, Gensigk F, Board T, Kendoff D, Krehmeier U, Wolfhard U. Arthrodesis of the distal interphalangeal joint: description of a new

- technique and clinical follow-up at 2 years. *Arch Orthop Trauma Surg.* 2008;128(3):307–311.
2. McGuire DT, White CD, Carter SL, Solomons MW. Pyrocarbon proximal interphalangeal joint arthroplasty: outcomes of a cohort study. *J Hand Surg Eur Vol.* 2012;37(6):490–496.
  3. Kalichman L, Hernandez-Molina G. Hand osteoarthritis: an epidemiological perspective. *Semin Arthritis Rheum.* 2010;39(6):465–476.
  4. Walker P. Laxity, flexibility and stability. In: Walker P, ed. *Human Joints and their Artificial Replacement.* Springfield, IL: Charles C Thomas; 1977:167–210.
  5. Swanson AB. Finger joint replacement by silicone rubber implants and the concept of implant fixation by encapsulation. *Ann Rheum Dis.* 1969;28(5):47–55.
  6. Linscheid RL, Murray PM, Vidal M-A, Beckenbaugh RD. Development of a surface replacement arthroplasty for proximal interphalangeal joints. *J Hand Surg Am.* 1997;22(2):286–298.
  7. Minamikawa Y, Imaeda T, Amadio PC, Linscheid RL, Cooney WP, An K-N. Lateral stability of proximal interphalangeal joint replacement. *J Hand Surg Am.* 1994;19(6):1050–1054.
  8. Meier R, Schulz M, Krimmer H, Stütz N, Lanz U. Der Finger-mittelgelenkersatz mit Pyrocarbonprothesen. *Oper Orthop Traumatol.* 2007;19(1):1–15.
  9. Field J. Two to 5 year follow-up of the LPM ceramic coated proximal interphalangeal joint arthroplasty. *J Hand Surg Eur Vol.* 2008;33(1):38–44.
  10. Iselin F, Conti E. Long-term results of proximal interphalangeal joint resection arthroplasties with a silicone implant. *J Hand Surg Am.* 1995;20(3 Pt 2):S95–S97.
  11. Takigawa S, Meletioui S, Sauerbier M, Cooney WP. Long-term assessment of swanson implant arthroplasty in the proximal interphalangeal joint of the hand. *J Hand Surg Am.* 2004;29(5):785–795.
  12. Wesemann A, Flugel M, Mamarvar M. [Moje prosthesis for the proximal interphalangeal joint]. *Handchir Mikrochir Plast Chir.* 2008;40(3):189–196.
  13. Daecke W, Veyel K, Wieloch P, Jung M, Lorenz H, Martini AK. Osseointegration and mechanical stability of pyrocarbon and titanium hand implants in a load-bearing in vivo model for small joint arthroplasty. *J Hand Surg Am.* 2006;31(1):90–97.
  14. Herren DB, Schindele S, Goldhahn J, Simmen BR. Problematic bone fixation with pyrocarbon implants in proximal interphalangeal joint replacement: short-term results. *J Hand Surg Br.* 2006;31(6):643–651.
  15. Pritsch T, Rizzo M. Reoperations following proximal interphalangeal joint nonconstrained arthroplasties. *J Hand Surg Am.* 2011;36(9):1460–1466.
  16. Ono S, Shauver MJ, Chang KWC, Chung KC. Outcomes of pyrolytic carbon arthroplasty for the proximal interphalangeal joint at 44 months' mean follow-up. *Plast Reconstr Surg.* 2012;129(5):1139–1150.
  17. Chamay A. A distally based dorsal and triangular tendinous flap for direct access to the proximal interphalangeal joint. *Ann Chir Main.* 1988;7(2):179–183.
  18. Beaton DE, Wright JG, Katz JN. Development of the QuickDASH: comparison of 3 item-reduction approaches. *J Bone Joint Surg Am.* 2005;87(5):1038–1046.
  19. Gummesson C, Ward M, Atroshi I. The shortened disabilities of the arm, shoulder and hand questionnaire (QuickDASH): validity and reliability based on responses within the full-length DASH. *BMC Musculoskeletal Disorders.* 2006;7:44.
  20. Offenbacher M, Ewert T, Sangha O, Stucki G. Validation of a German version of the 'Disabilities of Arm, Shoulder and Hand' questionnaire (DASH-G). *Z Rheumatol.* 2003;62(2):168–177.
  21. Macey AC, Burke FD, Abbott K, et al. Outcomes of hand surgery. British Society for Surgery of the Hand. *J Hand Surg Br.* 1995;20(6):841–855.
  22. Dias JJ, Bhowal B, Wildin CJ, Thompson JR. Assessing the outcome of disorders of the hand: Is the patient evaluation measure reliable, valid, responsive and without bias? *J Bone Joint Surg Br.* 2001;83(2):235–240.
  23. Drake ML, Segalman KA. Complications of small joint arthroplasty. *Hand Clin.* 2010;26(2):205–212.
  24. Pellegrini VD Jr, Burton RI. Osteoarthritis of the proximal interphalangeal joint of the hand: arthroplasty or fusion? *J Hand Surg Am.* 1990;15(2):194–209.
  25. Murray PM. Surface replacement arthroplasty of the proximal interphalangeal joint. *J Hand Surg Am.* 2007;32(6):899–904.
  26. Bravo CJ, Rizzo M, Hormel KB, Beckenbaugh RD. Pyrolytic carbon proximal interphalangeal joint arthroplasty: results with minimum two-year follow-up evaluation. *J Hand Surg Am.* 2007;32(1):1–11.
  27. Hume MC, Gellman H, McKellop H, Brumfield RH Jr. Functional range of motion of the joints of the hand. *J Hand Surg Am.* 1990;15(2):240–243.
  28. Branam BR, Tuttle HG, Stern PJ, Levin L. Resurfacing arthroplasty versus silicone arthroplasty for proximal interphalangeal joint osteoarthritis. *J Hand Surg Am.* 2007;32(6):775–788.
  29. Proubasta IR, Lamas CG, Natera L, Millan A. Silicone proximal interphalangeal joint arthroplasty for primary osteoarthritis using a volar approach. *J Hand Surg Am.* 2014;39(6):1075–1081.
  30. Simmen BR. Der palmare Zugang zur Arthroplastik des proximalen Interphalangeal-Finger-Gelenks. *Operat Orthop Traumatol.* 1993;5(2):112–123.
  31. Herren D, Simmen B. Palmar approach in flexible implant arthroplasty of the proximal interphalangeal joint. *Clin Orthop Relat Res.* 2000;371:131–135.
  32. Herren DB, Keuchel T, Marks M, Schindele S. Revision arthroplasty for failed silicone proximal interphalangeal joint arthroplasty. Indications and 8-year results. *J Hand Surg Am.* 2014;39(3):462–466.
  33. Daecke W, Kaszap B, Martini AK, Hagen FW, Rieck B, Jung M. A prospective, randomized comparison of 3 types of proximal interphalangeal joint arthroplasty. *J Hand Surg Am.* 2012;37(9):1770–1779.
  34. Nelson GN, Wu T, Galatz LM, Yamaguchi K, Keener JD. Elbow arthroscopy: early complications and associated risk factors. *J Shoulder Elbow Surg.* 2014;23(2):273–278.
  35. Chao ST, Joyce MJ, Suh JH. Treatment of heterotopic ossification. *Orthopedics.* 2007;30(6):457–464.
  36. Chung KC, Ram AN, Shauver MJ. Outcomes of pyrolytic carbon arthroplasty for the proximal interphalangeal joint. *Plast Reconstr Surg.* 2009;123(5):1521–1532.
  37. Sweets TM, Stern PJ. Pyrolytic carbon resurfacing arthroplasty for osteoarthritis of the proximal interphalangeal joint of the finger. *J Bone Joint Surg Am.* 2011;93(15):1417–1425.
  38. Reissner L, Schindele S, Hensler S, Marks M, Herren DB. Ten year follow-up of pyrocarbon implants for proximal interphalangeal joint replacement. *J Hand Surg Eur Vol.* 2014;39(6):582–586.
  39. Heers G, Springorum HR, Baier C, Götz J, Grifka J, Renkawitz T. Proximal interphalangeal joint replacement with an unconstrained pyrocarbon prosthesis (Ascension): a long-term follow-up. *J Hand Surg Eur Vol.* 2013;38(6):680–685.